

See discussions, stats, and author profiles for this publication at: <https://www.researchgate.net/publication/329984370>

A novel reconstructive strategy for pancreaticoduodenectomy following Roux-en-Y distal gastrectomy

Article in *Il Giornale di Chirurgia - Journal of Surgery* · November 2018

CITATION

1

READS

40

9 authors, including:



Salvatore Fedele
Policlinico di Bari

20 PUBLICATIONS 88 CITATIONS

SEE PROFILE



Cinzia Bizzoca
Policlinico di Bari

17 PUBLICATIONS 393 CITATIONS

SEE PROFILE



Antonella Delvecchio
Ospedale Generale Regionale "F. Mjulli"

53 PUBLICATIONS 402 CITATIONS

SEE PROFILE



Vincenzo Papagni
IRCCS Saverio de Bellis

34 PUBLICATIONS 1,296 CITATIONS

SEE PROFILE

A novel reconstructive strategy for pancreaticoduodenectomy following Roux-en-Y distal gastrectomy

S. FEDELE¹, C. BIZZOCA², A. DELVECCHIO¹, S. LAFRANCESCHINA¹,
V. PAPAGNI¹, A. PICCIARIELLO¹, S. PISICCHIO¹, R. BASILE³, L. VINCENTI²

SUMMARY: A novel reconstructive strategy for pancreaticoduodenectomy following Roux-en-Y distal gastrectomy.

S. FEDELE, C. BIZZOCA, A. DELVECCHIO, S. LAFRANCESCHINA,
V. PAPAGNI, A. PICCIARIELLO, S. PISICCHIO, R. BASILE, L. VINCENTI

The rate of pancreaticoduodenectomy (PD) performed for both benign and malignant periampullary diseases has increased. In addition, Roux-en-Y reconstruction after distal gastrectomy for cancer or ulcer is still widely used. Therefore, a surgeon may be confronted with a partially-gastrectomized patient who needs a PD. This is a very challenging circumstance for surgeons because of adhesions, bloodstream, anatomical changes and length of the remnant intestine.

In our experience, we performed two pancreaticoduodenectomies

after distal gastrectomy in patients with periampullary tumors. We preserve gastrojejunal anastomosis and perform an end-to-side pancreaticojejunostomy (PJ) on the afferent limb of gastrojejunal anastomosis and a termino-lateral hepaticojejunal anastomosis on an independent transmesocolic Roux-en-Y limb.

In literature, few cases of PD after distal gastrectomy are reported and most of them consider only PD after Billroth II reconstruction. Many authors have demonstrated pancreaticogastrostomy (PG) is superior to PJ in terms of lower risk of pancreatic and biliary fistula, but it is not possible to anastomose pancreas stump with gastric wall in patients who have been undergone distal gastrectomy. For this reason, we retrospectively review our experience about PD following distal gastrectomy and suggest a novel standardized technique which allow surgeons to benefit from same advantages of a typical PG also in this group of patients.

KEY WORDS: Pancreaticoduodenectomy - Distal gastrectomy - Roux-en-Y reconstruction -
Pancreaticojejunostomy - Pancreaticogastrostomy

Introduction

Gastric cancer incidence has fallen over the past decades along with the frequency of elective gastric resection for gastric or duodenal ulcers has decreased between 80 and 97% (1, 2). At the same time, the rate of pancreaticoduodenectomy (PD) performed for both benign and malignant diseases of the periampullary region has increased (3). Therefore, the scenario of a partially-gastrectomized patient who needs a PD is not so uncommon. In literature, few

cases of PD in patients who have previously undergone partial gastrectomy are reported (4-6). Performing PD in these patients is challenging because of adhesions, bloodstream, anatomical changes and length of the remnant intestine.

Several techniques have been proposed to restore pancreatic digestive continuity (7), but the issue of the best reconstructive strategy remains controversial. However, a recent meta-analysis (8) has demonstrated superiority of pancreaticogastrostomy (PG) over pancreaticojejunostomy (PJ) in terms of pancreatic fistula rate but it is not possible to perform a PG in partially-gastrectomized patient. This study retrospectively reviews our experience with PD following distal gastrectomy. Although our series consists of only two patients, we suggest a novel standardized PJ which allow surgeons to benefit from same advantages of a typical PG.

¹ Department of Emergency and Transplantation of Organs, University "A. Moro" of Bari, Bari, Italy

² General Surgery Unit, Policlinico of Bari, Bari, Italy

³ General Surgery Unit, "San Paolo" Hospital, Bari, Italy

Corresponding author: Salvatore Fedele,
e-mail: salvatorefedele.md@gmail.com

Case reports

Case 1

A seventy-year-old woman with a neoplasm of the pancreatic head was admitted to our hospital for obstructive jaundice. The histopathologic examination of the endoscopic biopsies revealed an adenocarcinoma. A Roux-en-Y distal gastrectomy (Figure 1) for non-Hodgkin lymphoma and a colecistectomy for empyema emerged from her history. During the surgery, a distal gastrectomy was evidenced with a gastrojejunal anastomosis, a Roux-en-Y transmesocolic loop and a jejuno-jejunal anastomosis 30 centimeters downstream of the duodenojejunal flexure. A PD was performed with a vascular resection and reconstruction of retropancreatic portal vein. The patient was discharged from the hospital after nine days with no postoperative complications.

Case 2

A sixty-eight-year-old man was referred to our hospital due to a persistent abdominal pain. His history included a Roux-en-Y reconstruction after distal gastrectomy (Figure 1) and adjuvant chemotherapy for signet-ring cell carcinoma of the stomach. He underwent TC and MRI with residual duodenal neoplasm evidence. At explorative laparotomy, preoperative imaging diagnosis was confirmed. It was recognized Roux-en-Y limb, gastro-jejunal and jejuno-jejunal anastomosis and hard tissue of the duodenum evidence. During PD, middle colic vessels ligation was required for neoplastic infiltration and colic resection and anastomosis were performed. There were no postoperative complications and the patient was discharged after ten days.

The reconstructive phase for both patients consisted of a PJ and a hepaticojejunal anastomosis (Figure 2). Gastro-jejunal anastomosis was preserved. An end-to-side PJ was performed on the afferent limb of gastro-jejunal anastomosis: a Wirsung stented duct-to-mucosa anastomosis with a 4-0 monolayer absorbable suture and a sero-muscular jejunal – pancreatic stump anastomosis with a 3-0 monolayer non-absorbable suture. Wirsung stent was taken out through gastric wall. A termino-lateral hepaticojejunal anastomosis was performed with a 4-0 monolayer absorbable suture on an independent transmesocolic Roux-en-Y limb which was anastomosed with the efferent loop of the gastrojejunal anastomosis.

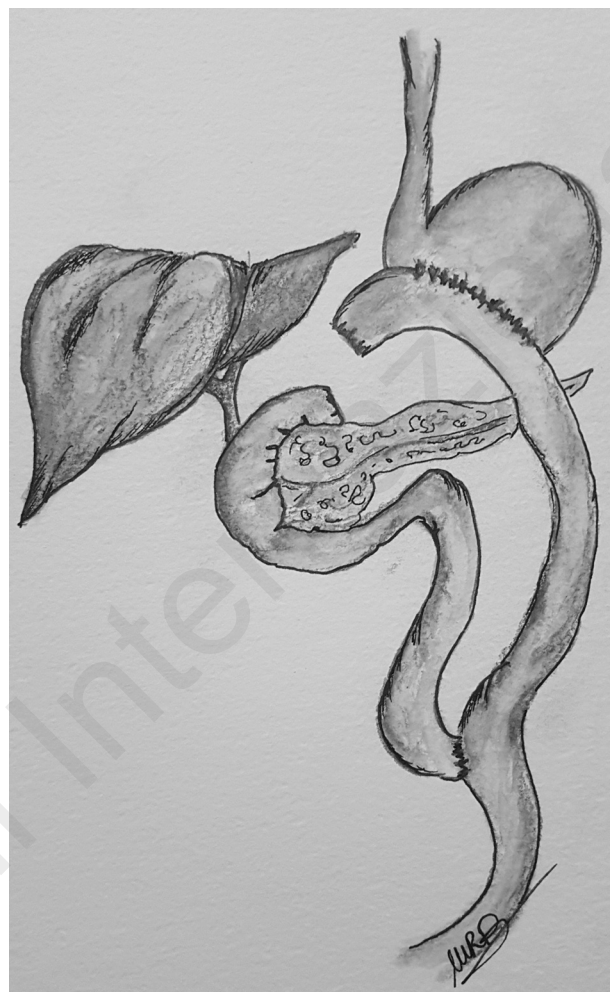

Figure 1 - Anatomy after a Roux-en-Y distal gastrectomy. PD is a challenging surgery in these patients.

Discussion

Roux-en-Y reconstruction after distal gastrectomy for cancer or ulcer is widely used. A recent meta-analysis (9) has showed it provides less of reflux symptoms with significantly reduction of reflux gastritis and esophagitis and improvement of quality of life. However, it is more time-consuming and has a higher complication rate than other methods (10). Nevertheless, many surgeons prefer Roux-en-Y reconstruction due to the decreased likelihood of bile reflux which increases the risk of cancer in the remnant stomach.

In literature, there are few papers (4-6) with small numbers of cases about PD in patients who have been undergone partial gastrectomy. Oida et al. (4) compared Imanaga's-Cattell's and Child's recon-

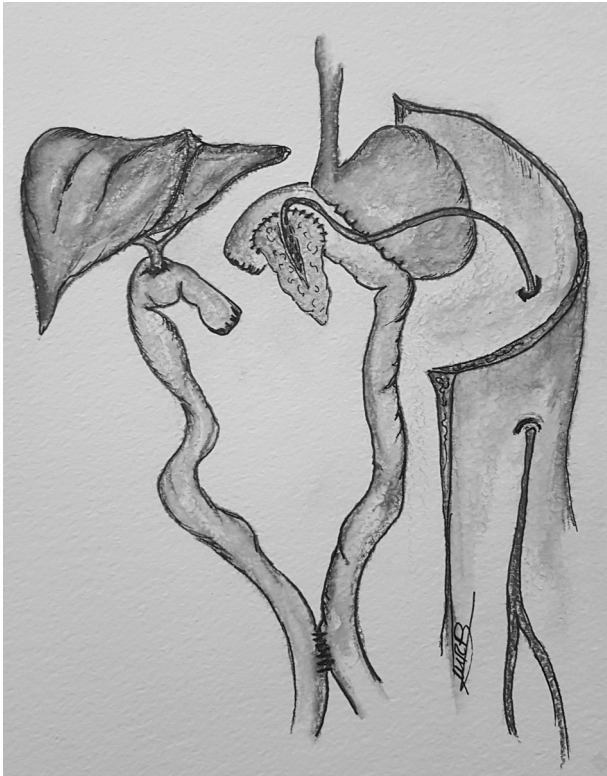


Figure 2 - Gastro-jejunal anastomosis is preserved and is performed a PJ on the afferent limb of gastro-jejunal anastomosis and a hepatico-jejunal anastomosis on an independent transmesocolic Roux-en-Y limb.

structions after PD and demonstrated the superiority of the second one in terms of delayed gastric emptying, but they did not use Roux-en-Y reconstruction. Bechi et al. (5) proposed a standardization of reconstructive strategy after PD according to the length of the afferent limb, but they considered Billroth II and not Roux-en-Y previous partial gastrectomy. Kawamoto Y. et al. (6) took into account only PD in Billroth II reconstruction too.

In this paper, we suggest a standardization of PD reconstruction in previous Roux-en-Y distal gastrectomy. As in Billroth II reconstructions (5), in Roux-en-Y a re-resection of gastro-jejunal anastomosis can be avoided in order to decrease surgical time and risks of complications. If re-resection is an unavoidable choice because of vascular or oncologic reasons, greater stasis of bile or pancreatic juice in the afferent limb may occur in Billroth II as well as in our Roux-en-Y reconstruction with greater risk of pan-

creatic fistula.

Anastomose pancreas stump with the afferent limb of gastro-jejunal anastomosis of Roux-en-Y limb represent a solution to perform a PJ with same well-known advantages of PG. Pancreatic fistula is the most important and frequent complication after PD. Recent randomized controlled trials (11-13) and a recent meta-analysis (14) have demonstrated PG is superior than PJ in terms of pancreatic fistula, biliary fistula, intra-abdominal fluid collection and hospital length of stay. About pancreatic fistula, it may be linked to the prevention of pancreatic enzymes activation by gastric acid and consequently of the anastomotic leak. Postoperative nasogastric decompression may continuously remove pancreatic and gastric secretions decreasing any anastomosis tension. Some authors (15) have also demonstrated incidence of biliary fistula is significantly lower in PG than in PJ. The presence in a nearby area of a double anastomosis (PJ and hepatico-jejunal) in PJ rather than a single biliary anastomosis in PG may be the main reason why pancreatic and biliary fistula are associated in PJ in 42.9% of patients (14). Kawamoto Y. et al. (6) showed a reconstruction after PD with PJ and hepaticojejunostomy on an autonomous Roux-en-Y limb, but two patients of four (50%) presented a pancreatic fistula with a long hospital stay.

We perform a PJ which is functionally a PG. Pancreatic enzymes inactivation and nasogastric decompression effect are provided and pancreatic and biliary anastomosis are far away from each other and performed on two different limbs.

Conclusions

PD in patients who have been undergone distal gastrectomy is a challenging surgery. Our experience shows Roux-en-Y reconstruction preserving gastro-jejunal anastomosis with PJ on its afferent loop and hepatico-jejunal anastomosis on an independent limb may be an effective and safe alternative to typical Billroth II. This standardized strategy may help surgeon to avoid most important postoperative complications such as pancreatic fistula.

References

1. Paimela H, Paimela L, Myllykangas-Luosujärvi R, Kivilaakso E. Current features of peptic ulcer disease in Finland: incidence of surgery, hospital admissions and mortality for the disease during the past twenty-five years. *Scandinavian Journal of Gastroenterology*. 2002;37(4):399-403.
2. Schwesinger WH, Page CP, Sirinek KR, Gaskill HV 3rd, Melnick G, Strodel WE. Operations for peptic ulcer disease: paradigm lost. *Journal of Gastrointestinal Surgery*. 2001;5(4):438-443.
3. Matsuno S, Egawa S, Fukuyama S, Motoi F, Sunamura M, Isaji S, Imaizumi T, Okada S, Kato H, Suda K, Nakao A, Hiraoka T, Hosotani R, Takeda K. Pancreatic cancer: current status of treatment and survival of 16 071 patients diagnosed from 1981–1996, using the Japanese National Pancreatic Cancer Database. *Int J Clin Oncol*. 2000;5(3):153-157.
4. Oida T, Mimatsu K, Kawasaki A, Kano H, Kuboi Y, Amano S. Reconstruction following pancre-aticoduodenectomy for patients who have previously undergone partial gastrectomy. *Hepatogastroenterology*. 2010;57:149-154.
5. Bechi P, Dioscoridi L. Reconstructive strategy after pancreaticoduodenectomy in partially gastrectomized patients. *J Pancreas*. 2015;16(2):198-200.
6. Kawamoto Y, Ome Y, Kouda Y, Saga K, Park T, Kawamoto K. Pancreaticoduodenectomy following gastrectomy reconstructed with Billroth II or Roux-en-Y method: Case series and literature review. *Int J Surg Case Rep*. 2017;35:106-109.
7. Yang SH, Dou KF, Sharma N, Song WJ. The methods of reconstruction of pancreatic digestive continuity after pancreaticoduodenectomy: a meta-analysis of randomized controlled trials. *World J Surg*. 2011 Oct;35(10):2290-2297.
8. Hallet J, Zih FS, Deobald RG, Scheer AS, Law CH, Coburn NG, Karanickolas PJ. The impact of pancreaticojejunostomy versus pancreaticogastrostomy reconstruction on pancreatic fistula after pancreaticoduodenectomy: meta-analysis of randomized controlled trials. *HPB (Oxford)*. 2015 Feb;17(2):113-122.
9. Zong L, Chen P. Billroth I vs. Billroth II vs. Roux-en-Y following distal gastrectomy: a meta-analysis based on 15 studies. *Hepatogastroenterology*. 2011 Jul-Aug;58(109):1413-24.
10. Imamura H, Takiguchi S, Yamamoto K, Hirao M, Fujita J, Miyashiro I, Kurokawa Y, Fujiwara Y, Mori M, Doki Y. Morbidity and mortality results from a prospective randomized controlled trial comparing Billroth I and Roux-en-Y reconstructive procedures after distal gastrectomy for gastric cancer. *World J Surg*. 2012 Mar;36(3):632-7.
11. Figueras J, Sabater L, Planellas P, Muñoz-Fornier E, Lopez-Ben S, Falgueras L, Sala-Palau C, Albiol M, Ortega-Serrano J, Castro-Gutierrez E. Randomized clinical trial of pancreaticogastrostomy versus pancreaticojejunostomy on the rate and severity of pancreatic fistula after pancreaticoduodenectomy. *Br J Surg*. 2013 Nov;100(12):1597-1605.
12. Topal B, Fieuws S, Aerts R, Weerts J, Feryn T, Roeyen G, Bertrand C, Hubert C, Janssens M, Closser J; Belgian Section of Hepatobiliary and Pancreatic Surgery. Pancreaticojejunostomy versus pancreaticogastrostomy reconstruction after pancreaticoduodenectomy for pancreatic or peri-ampullary tumours: a multicentre randomized trial. *Lancet Oncol*. 2013 Jun;14(7):655-662.
13. Wellner HF, Sick O, Olschewski M, Adam U, Hopt UT, Keck T. Randomized controlled single-centre trial comparing pancreato-gastrostomy versus pancreaticojejunostomy after partial pan-creato-duodenectomy. *J Gastrointest Surg*. 2012 Sep;16(9):1686-1695.
14. Liu FB, Chen JM, Geng W, Xie SX, Zhao YJ, Yu LQ, Geng XP. Pancreaticogastrostomy is associated with significantly less pancreatic fistula than pancreaticojejunostomy reconstruction after pancreaticoduodenectomy: a meta-analysis of seven randomized controlled trials. *HPB (Oxford)*. 2015 Feb;17(2):123-130.
15. Bassi C, Falconi M, Molinari E, Mantovani W, Butturini G, Gumbs AA, Salvia R, Pederzoli P. Duct-to-mucosa versus end-to-side pancreaticojejunostomy reconstruction after pancreaticoduodenectomy: results of a prospective randomized trial. *Surgery*. 2003 Nov;134(5):766-771.